CHAPTER 36

Sports medicine and sports injuries

Learning objectives

- To review some common sports injuries
- To understand the basics of history, physical examination and imaging for common injuries
- To assess the patient and offer treatment and rehabilitation plans

INTRODUCTION

In addition to a clinical assessment, an understanding of the biomechanics of injury associated with sporting activity can facilitate diagnosis, treatment and management of the patient according to their competitive level and recovery goals. This chapter aims to provide a brief clinically directed overview of selected common injuries, with the examples associated with a wide variety of sports.

DIAGNOSIS OF SPORTS INJURIES

Within the history, there are some additional questions that need to be asked when treating a patient with a sports injury:

- How was the injury sustained?
- When was the injury sustained?
- What intervention(s) has the patient tried and what rehabilitation have they had?
- How many hours of training is the patient doing and has this changed recently?
- Has the patient had a previous injury?
- What are the patient's competitive goals?

The examination should follow the general system described in *Chapter 35*.

COMMONLY ENCOUNTERED REGIONAL INJURIES

Shoulder

Shoulder instability and rotator cuff tear

Background

Shoulder injuries affect athletes of all ages; however, the distribution of shoulder injuries varies between young and older participants. In athletes younger than 30 years old, especially those participating in contact sports, anterior shoulder dislocations can occur in instances of traumatic or forced shoulder abduction and external rotation. Unfortunately, such dislocations, even if reduced, lead to some degree of stretching of the anterior capsule and tearing of the anteroinferior labrum, which places the patient at risk for further instability events. In older patients who experience falls and sustain the same anterior shoulder dislocations, additional pathologies, including rotator cuff tears, can occur.

History and physical examination

Patients who sustain a shoulder dislocation often describe a violent injury event such as a fall or tackle with the arm in some degree of abduction. Patients will often describe a sensation of their shoulder feeling out of place, especially if the shoulder does not spontaneously reduce. An important component of the history involves the details of the dislocation(s): self-reduction versus emergency department reduction, length of time dislocated prior to reduction, prior dislocations, extremity numbness, general ligamentous laxity and activity profile – all of these details have implications for management. Examination in the acute period should focus on evaluating anterior apprehension or subjective patient discomfort and fear of re-dislocation in the positions of abduction and external rotation of the shoulder, as well as rotator cuff strength and neurovascular integrity, especially of the axillary nerve (see *Further reading*).[1,2]

Imaging

Radiographs, including at least true anteroposterior (AP) or Grashey, scapular Y, axillary or Velpeau views, should be obtained in all circumstances and evaluated to confirm glenohumeral reduction while ruling out associated fractures, such as Hill–Sachs deformities or glenoid rim fractures.

Rudolph Grashey, 1876–1950, Professor of Roentgenology, University of Cologne, Cologne, Germany.
Alfred-Armand-Louis-Marie Velpeau, 1795–1867, French anatomist and surgeon.
Harold Arthur Hill, 1901–1973, radiologist, San Francisco, CA, USA.
Maurice David Sachs, 1909–1987, radiologist, San Francisco, CA, USA.

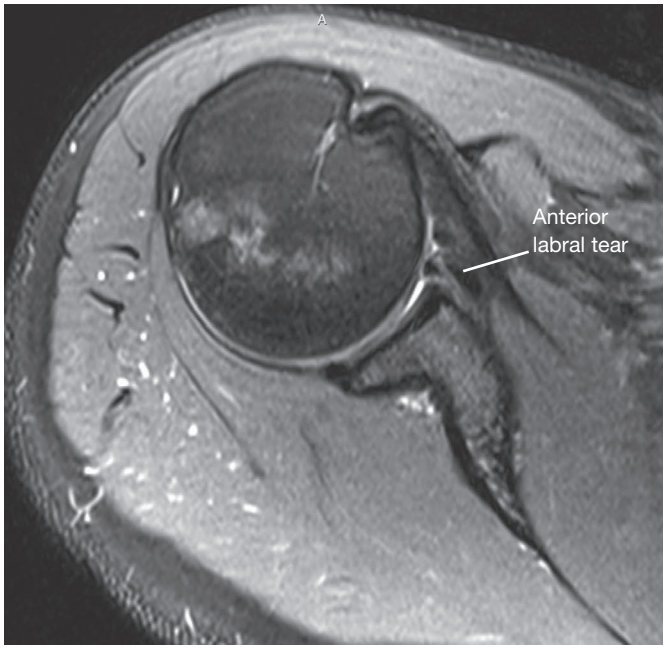

Figure 36.1 Axial fluid-sensitive magnetic resonance image of the shoulder demonstrating an anterior labral tear.

Specific views, including the West Point axillary and the Stryker notch views, can be helpful for evaluating glenoid rim or Bankart fractures or Hill–Sachs lesions, respectively. In cases of recurrent instability where glenoid bone loss is suspected, computed tomography (CT) with or without three-dimensional reconstruction can be helpful in further determining the extent of bone loss. In most instances of anterior instability, magnetic resonance imaging (MRI) is recommended (*Figure 36.1*) to evaluate for concomitant soft-tissue injuries, including rotator cuff tears, humeral avulsions of the glenohumeral ligament (HAGL), glenolabral articular disruptions (GLAD) or anterior labrum periosteal sleeve avulsion (ALPSA).

Treatment

After reduction of an acute anterior glenohumeral dislocation, patients are typically placed in a sling for the first few days.[2] It is important to begin early gentle range of motion of the shoulder through pendulum exercises but also to continue to move the elbow, wrist and digits actively to maintain range of motion in those distal joints. The initial period is then progressed to increased passive and then active and active-assisted range of motion of the shoulder. Once range of motion has returned to near normal, rotator cuff and scapular strengthening is progressed. Surgery is considered for even first-time dislocators based upon stratification of several factors, including younger age, activity profile and pathology present on imaging. Furthermore, depending upon the pathology present, the surgical options exist on a continuum from arthroscopic capsulolabral repair to open capsulolabral repair and capsular shift to glenoid bony augmentation procedures.[3,4] Regardless of the treatment method chosen, athletes are cleared to return to sport once their range of motion and strength have returned to normal levels.

Older athletes who acutely tear their rotator cuff in the setting of shoulder dislocations can be considered for acute rotator cuff repair.[5] The treatment of rotator cuff tears has evolved over several years and current techniques of arthroscopic repair with a knotless, linked, double-row construct (*Figure 36.2*) have demonstrated excellent patient-reported outcomes with low re-tear rates.

Differential diagnosis

- Proximal humerus fracture.
- Greater tuberosity fracture.
- Acromioclavicular joint separation.

Summary box 36.1

Shoulder instability

- Dislocations occur in instances of traumatic or forced shoulder abduction and external rotation
- Details of the reduction, time dislocated, history of prior dislocations, general ligamentous laxity and activity profile have implications for management
- Radiographs to confirm glenohumeral reduction include true AP or Grashey, scapular Y, axillary or Velpeau views
- A sling should be used for a few days following an acute anterior glenohumeral dislocation
- Surgery is considered based upon stratification of several factors, including younger age, activity profile and pathology present on imaging

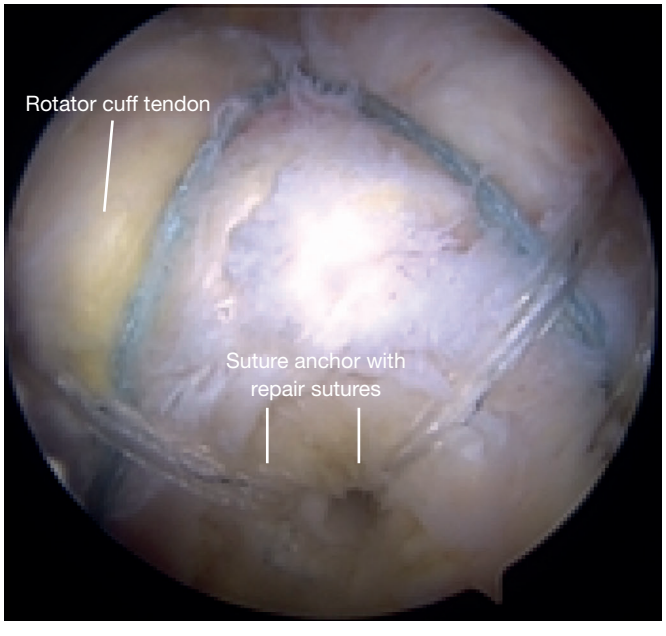

Figure 36.2 Shoulder arthroscopic image of a rotator cuff repair viewed from the subacromial space through a lateral portal with a 30° arthroscope.

William Schamel Stryker, 1916–2015, orthopedic surgeon and Captain in the United States Navy.
Arthur Sydney Blundell Bankart, 1879–1951, orthopaedic surgeon, The Middlesex Hospital, London, UK.

Elbow

Ulnar collateral ligament tear

Background

The anterior band of the ulnar collateral ligament (UCL) is the primary stabiliser to valgus stress at the elbow. Anatomically this ligament courses from the medial epicondyle of the humerus to the sublime tubercle of the ulna. Although it can be injured acutely through mechanisms of elbow dislocations, pathology is most frequently encountered in repetitive throwing athletes, such as baseball pitchers and javelin throwers. In the late cocking and early acceleration phases of throwing the ligament is under its maximum stress and at this stage is at the highest risk of rupture and chronic attenuation.

History and physical examination

Throwers who sustain ruptures of their UCL commonly present with two sets of complaints. Rarely, the thrower will recall an acute episode when they heard a pop in the throwing cycle followed by medial elbow pain and pain worse with throwing. The vast majority of throwers complain of medial elbow pain and tightness coupled with decreased velocity that comes on more insidiously. Examination focuses on provocative manoeuvres that are specific for the UCL, including valgus stress and the moving valgus stress tests or milking manoeuvre (*Figure 36.3*), in which the examiner provides a valgus stress through elbow range of motion.[6] Pain at the medial elbow during these manoeuvres is specific for UCL pathology. The examiner should also focus on both ulnar nerve sensory and motor symptoms in the hand in addition to ulnar nerve subluxation as these pathologies can affect the proposed treatment algorithm.

Imaging

Radiographs of the elbow include a series of AP, lateral, internal and external oblique views. These can help rule out other commonly encountered phenomena seen in overhead throwing athletes, including medial epicondyle fractures, posteromedial impingement and capitellar osteochondral defects. When UCL pathology is suspected, dynamic ultrasound is a helpful imaging modality to help characterise the location of the UCL pathology. Moreover, it permits easy examination of the contralateral elbow, which can help to quantify incongruities in medial elbow joint space gapping, an indirect gauge of tear severity. MRI is commonly obtained to precisely define the location of the UCL tear as well as to better evaluate the articular cartilage and the flexor pronator mass, which can also commonly be affected.

Treatment

Conservative management of UCL injuries is considered first-line treatment and typically entails a period of several months of cessation of throwing followed by structured rehabilitation that includes strengthening of secondary stabilising muscles about the elbow and a gradual return of throwing.[6] The use of biological injections, including platelet-rich plasma, has been proposed for partial-thickness ligament tears in some centres, but more clinical evidence is required. Although ligament repair with an internal brace has recently been demonstrated to have efficacy in certain types of tears, the gold standard for surgical treatment is UCL reconstruction or Tommy John surgery. The surgery involves an autograft tendon harvest, commonly utilising the ipsilateral palmaris longus tendon, and reconstruction of the ligament through bone tunnels in both the humerus and ulna.[6] This surgery can be coupled with *in situ* decompression or transposition of the ulnar nerve, if indicated. Ulnar reconstruction surgery is indicated for the highest level of throwers who wish to continue playing their respective sport, with return to sport taking anywhere from 12 to 18 months.

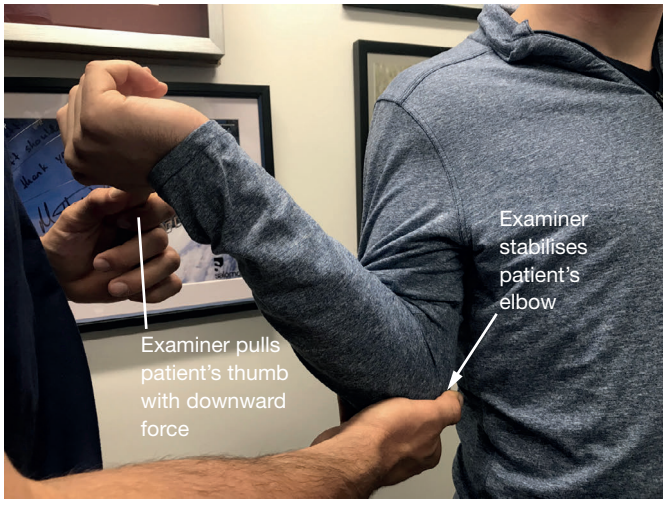

Figure 36.3 Demonstration of the milking manoeuvre. This is considered a positive test when this provocative manoeuvre elicits pain in the medial elbow, indicating ulnar collateral ligament injury.

Differential diagnosis

- Flexor pronator mass sprain.
- Ulnohumeral arthritis.
- Ulnar nerve compression or subluxation.
- Loose body.

Summary box 36.2

UCL tears

- Injury seen among repetitive throwing athletes
- Onset can be acute ('pop') or insidious with medial elbow pain, tightness and decreased throwing velocity
- Dynamic ultrasound or MRI can be used to characterise the location of the UCL pathology
- First-line treatment is conservative management with cessation of throwing followed by structured rehabilitation
- Surgical options include UCL reconstruction (gold standard) or ligament repair with an internal brace

Tommy John surgery, named after Thomas Edward John Jr, the first major league baseball pitcher who received an ulnar collateral ligament reconstruction in 1974.

Figure 36.4 Example of the C-sign for intra-articular hip pathology when asking a patient to demonstrate where they feel their pain.

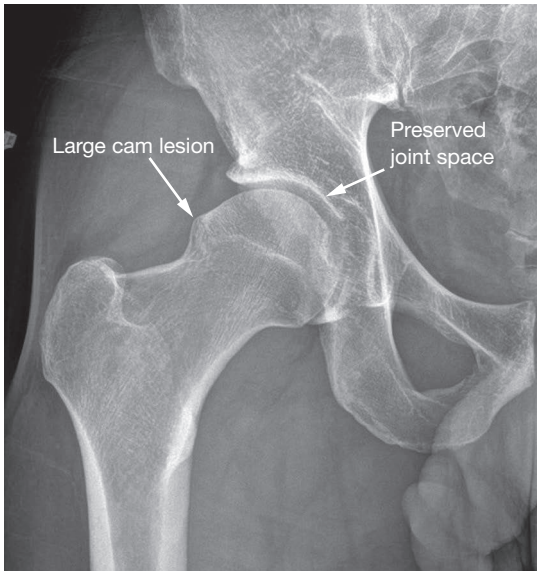

Figure 36.5 Anteroposterior right hip radiograph demonstrating a large cam lesion in the setting of the preserved hip joint space.

Hip

Femoroacetabular impingement and dysplasia

Background

Intra-articular hip derangements most commonly manifest as anterolateral groin pain in a characteristic distribution, referred to as a 'C-sign' (*Figure 36.4*). In a young patient, two common sources of groin pain with intra-articular origin are femoroacetabular impingement (FAI) and dysplasia. These conditions are considered in some detail in *Chapter 39* but are described here as they can present as a sports-related injury.

History and physical examination

Young patients with a history of groin pain or repetitive 'groin or hip flexor sprains' should be evaluated for dysplasia or FAI. Physical examination focuses on hip range of motion, strength, palpation and provocative manoeuvres. Some important manoeuvres include the FADIR examination, which stands for hip Flexion, ADduction and Internal Rotation, which is specific for impingement pathologies, but the FABER (Flexion, ABduction and External Rotation) manoeuvre as well as resisted hip flexion (Stinchfield testing) can also identify true intra-articular pathologies.[7]

Imaging

Initial imaging includes radiographs of the pelvis and the affected hip. Anteroposterior pelvis and false profile views can help determine lateral or anterior coverage of the acetabulum, respectively, while 45° Dunn lateral radiographs of the hip are the optimal projection for detecting the presence of a cam lesion (*Figure 36.5*). Three-dimensional imaging, including CT and MRI, is helpful for better defining the bony morphology and soft-tissue (i.e. labral) integrity, respectively.

Treatment

Once the correct diagnosis is determined both pathologies can initially be treated conservatively using anti-inflammatory drugs, physical therapy and at times intra-articular injection, for example corticosteroid. Should these modalities fail, both FAI and dysplasia have their own specific surgical interventions: arthroscopy (*Figure 36.6*) and osteotomy, respectively (see *Chapter 39*). Importantly, the aforementioned interventions are only a consideration prior to the development of joint space narrowing and osteoarthritis in an effort to preserve the hip joint.[7]

Differential diagnosis

- Adductor strain.
- Hip osteoarthritis.
- Athletic pubalgia.
- Lumbar radiculopathy.

Summary box 36.3

Femoroacetabular impingement and dysplasia

- Intra-articular hip derangements can manifest with anterolateral groin pain in a characteristic distribution ('C-sign')
- Consider pathologies in young patients with a history of groin pain or repetitive 'groin or hip flexor sprains'
- Initial imaging includes radiographs of the pelvis and the affected hip
- Three-dimensional imaging includes CT (bony morphology) and MRI (soft-tissue integrity)
- Conservative treatment involves using anti-inflammatory drugs, physical therapy and/or intra-articular injection
- Surgical interventions are arthroscopy (FAI) and osteotomy (dysplasia) prior to the development of joint space narrowing and osteoarthritis

Frank E Stinchfield, 1910–1992, American orthopaedic surgeon and founder of The Hip Society.
Denis M Dunn, 1916–2001, British orthopaedic surgeon.

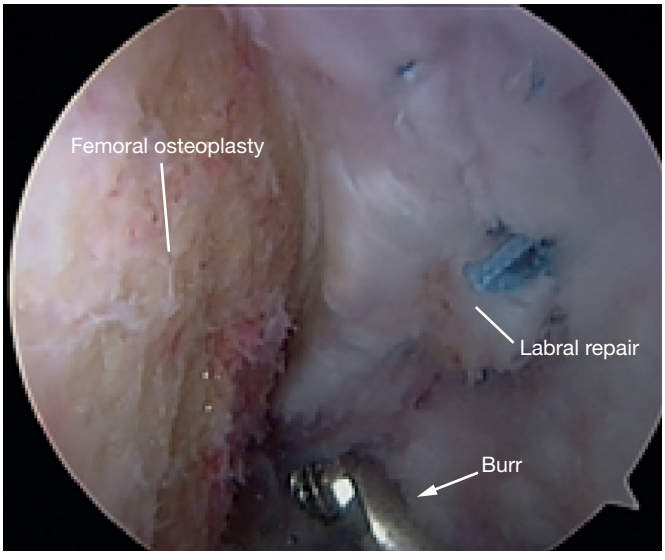

Figure 36.6 Hip arthroscopic image viewed through the mid-anterior portal with a 70° arthroscope.

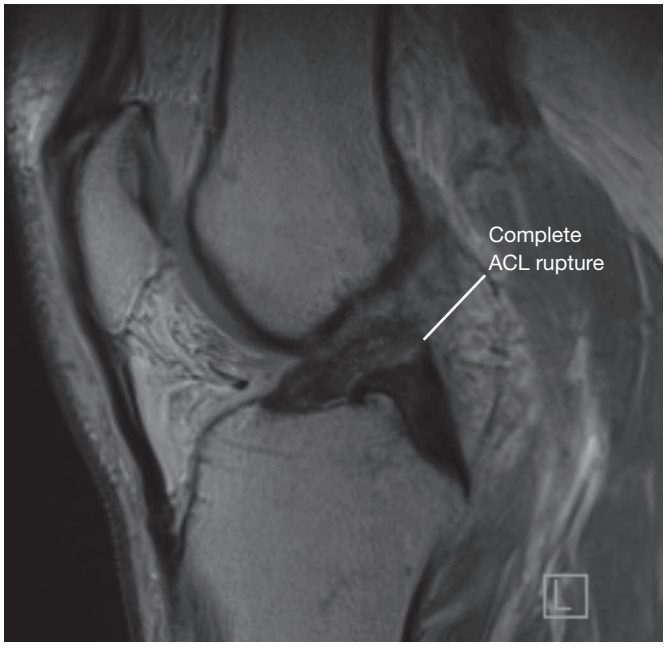

Figure 36.7 Sagittal proton density magnetic resonance image of the knee demonstrating a complete proximal anterior cruciate ligament (ACL) rupture.

Knee anterior cruciate ligament rupture with meniscus tear

Background

Acute knee injuries are extremely common in most sports that require jumping, twisting and contact. Sports with physical impact or tackling, such as rugby or American football, can result in contact knee injuries that often lead to varus or valgus stresses to the knee, resulting in collateral ligament injuries (i.e. lateral collateral ligament or medial collateral ligament) in addition to concomitant cruciate ligament, meniscus or articular cartilage injuries. More frequently, however, acute non-contact injuries of the knee lead to injury to the anterior cruciate ligament (ACL). The most common mechanism of these injuries is a deceleration when the knee falls into valgus and the tibia externally rotates, leading to a subluxation of the knee. These injuries are often associated with either medial or lateral meniscus injuries.

History and physical examination

Patients with an acute ACL injury will often report hearing or feeling a pop in their knee followed by a notable effusion and/or haemarthrosis. Once the effusion resolves, they may report a paucity of knee pain, often leading the patient to believe that the injury has healed itself. However, patients usually present to a physician after attempting subsequent cutting and pivoting activities, which can lead to recurrent instability. Given that the ACL's primary function is to restrict anterior translation of the tibia on the femur, the most commonly utilised tests to evaluate the competency of the ACL are the anterior drawer and Lachman tests (see *Chapter 35*).

Imaging

The initial evaluation of an acute knee injury with effusion and/or haemarthrosis necessitates radiographic evaluation. AP, lateral and merchant views are the minimum recommended. These radiographs can be useful for identifying any concomitant injuries, including fractures. A Segond fracture located on the anterolateral tibia is pathognomonic for an ACL injury. If an ACL injury is suspected by physical examination, an MRI is performed to better evaluate the intra-articular structures and to aid in surgical planning. A systematic evaluation of the MRI is necessary to ensure that no additional pathology is missed (*Figure 36.7*). 'Kissing lesions' of bony oedema seen on fluid-sensitive sequences on the posterolateral tibia and lateral femoral condyle are also pathognomonic for ACL rupture and represent the pivot shift knee subluxation seen in the setting of ACL rupture.

Treatment

ACL injuries can be managed conservatively through activity modification and bracing. Should these modalities fail, surgery is an excellent option for restoration of knee stability and to decrease the potential for further meniscal or articular cartilage degeneration. ACL repair has recently become a resurging option for proximal-type tears when the ACL can be restored back to its anatomic footprint on the femur. The bridge-enhanced ACL repair (BEAR) technique using a collagen scaffold is currently under clinical trial and may emerge as an option in the future. The gold standard for ACL, however, is reconstruction. In younger patients, large multicentre cohort studies have indicated that autograft reconstruction offers the best durability and lowest chance for re-rupture. Options for autograft reconstruction include bone–patellar tendon–bone, hamstring and quadriceps–tendon autografts. For older and

John W Lachman, 1919–2007, Professor and Chairman of the Orthopedic Department at Temple University in Philadelphia, PA, USA.
Paul Ferdinand Segond, 1851–1912, French surgeon who was a founder of obstetrics and also an expert of the knee, Paris, France.

low-demand patients with symptomatic instability, allograft tendon reconstruction provides an additional graft option.

Meniscal tears are frequently encountered in the setting of ACL rupture.[8] Common tear patterns encountered include radial tears, root tears and bucket-handle tears where the torn portion of the meniscus can flip like a bucket handle into the centre of the joint. Previously, meniscus tears were treated with partial excision to remove any mechanical disruptions and associated pain, but in recent years the joint preservation functions of the menisci as well as their contribution to stability of the knee have been better appreciated, leading to efforts to preserve as much meniscal tissue as possible, especially in younger patients. Various methods of meniscus repair are currently utilised to restore the meniscus anatomy, including all-inside devices, inside-out, outside-in and root repair techniques, the details of which are beyond the scope of this chapter. Biological strategies, to augment the repair, are being evaluated in some centres.

Differential diagnosis

- Patellar dislocation.
- Posterior cruciate ligament rupture.
- Medial collateral ligament knee rupture.
- Posterolateral corner knee ligament injury.
- Patellar tendon rupture.

Summary box 36.4

ACL ruptures

- Mechanism is commonly a non-contact pivoting injury or a direct impact to the lateral knee
- Patients often hear or feel a pop in their knee followed by a notable effusion and may experience instability when returning to cutting and pivoting activities
- Radiographic evaluation includes AP, lateral and merchant views
- MRI is performed to better evaluate the intra-articular structures, aid in surgical planning and ensure that no additional pathology is missed
- ACL injuries can be managed conservatively through activity modification and bracing
- Surgical options include ACL reconstruction (gold standard) and repair in certain select scenarios

Ankle

Low ankle sprains

Background

Ankle sprains are a common injury that can prevent athletes from competing. These injuries are prevalent in sports that involve cutting actions or uneven surfaces while running, such as basketball, rugby, soccer, football and trail running. The ankle primarily resists inversion through the lateral collateral ligament complex, which is composed of the anterior talofibular ligament (ATFL), posterior talofibular ligament (PTFL) and calcaneofibular ligament (CFL). The ATFL is the most frequently injured ligament in the complex; it attaches at the most distal aspect of the fibula and spans anteromedially to the lateral aspect of the talus to prevent inversion during plantarflexion. The CFL is the next most injured ligament; it attaches proximal and posterior to the ATFL origin on the fibula and traverses posteromedially to the lateral aspect of the calcaneus. The position and orientation of the CFL results in resistance against inversion of the ankle while dorsiflexed. The PTFL is the strongest ligament in the complex and is rarely involved in ankle sprains.

History and physical examination

Patients with ankle sprains can often recall the injury and will report the feeling of the ankle inverting. Post injury, many patients will have swelling and bruising on the lateral aspect of their ankle, which can travel to a dependent position on their foot. Examiners should perform all examination manoeuvres on the contralateral and ipsilateral sides to assist in comparisons. The patient may exhibit tenderness to palpation at the lateral collateral ligament complex. The anterior drawer test can be used to evaluate for ATFL injuries. In this test, the ankle is placed into mild plantarflexion while a posterior force is applied to the distal tibia and an anterior translation force is applied to the calcaneus. This test is positive when there is excessive anterior translation of the talus on the tibia compared to the contralateral side. The talar tilt examination evaluates both the CFL and the ATFL. This test is performed with mild plantarflexion of the foot, followed by stabilisation of the distal tibia with one hand while the other hand places varus stress on the talus. Excessive tilt during this manoeuvre is indicative of ATFL injury, whereas CFL injury is indicated by excessive tilt when placing the foot in slight dorsiflexion with varus stress on the talus being applied.

Imaging

Radiographs of the ankle are indicated if the patient fulfils any of the Ottawa ankle rules (***Table 36.1***). Foot radiographs are obtained if the patient has tenderness at the base of the fifth metatarsal or at the navicular bone or if they are unable to bear weight on the foot. Typically, radiographs include weight-bearing AP, mortise and lateral views along with a talar tilt view. These can help rule out other pathologies that may be contributing to ankle pain, such as various types of fractures or osteochondral lesions of the talus. If the examiner is concerned about a high ankle sprain, an external rotation radiograph can be obtained. MRI is not a standard modality utilised in the evaluation of ankle sprains but should be obtained for patients with chronic ankle pain or instability to evaluate for osteochondral lesions of the talus, tendon injury, anterolateral impingement or tibiofibular syndesmosis injury.

TABLE 36.1 Ottawa ankle rules.

- Bone tenderness along the distal 6 cm of the posterior margin or at the tip of the lateral malleolus
- Bone tenderness along the distal 6 cm of the posterior margin or at the tip of the medial malleolus
- Inability to bear weight at the time of the accident or at the time of examination

Treatment

Ankle sprains are often treated conservatively with rest, ice, compression and elevation. Athletes should limit

weight-bearing initially, with care being directed towards pain control, reducing swelling and proprioceptive exercises. Strengthening of the peroneal muscles and stretching can occur once the patient is able to tolerate bearing weight on the ankle. Consider supportive braces to further stabilise the ankle from inversion and eversion. Surgery is indicated in patients with persistent pain and recurrent ankle sprains. This can be achieved through anatomical reconstruction by imbrication of the attenuated ATFL with or without reinforcement using the inferior extensor retinaculum.[9] Several non-anatomical lateral ankle ligament reconstruction techniques have also been described for use in chronic ankle instability. The prognosis following an ankle sprain depends on the severity of the injury, but many patients are back participating in sports after a few weeks.

Differential diagnosis

- Anterolateral ankle impingement.
- Peroneal tendon disruption.
- Fracture of the lateral talar process.
- Syndesmotic sprain.
- Osteochondral lesion of the talus.
- Malleolar fracture.
- Lateral process of the calcaneus fracture.

Summary box 36.5

Low ankle sprains

- Common injury among athletes in sports that involve cutting actions or running on uneven surfaces
- Patients may report the feeling of the ankle inverting and present with subsequent swelling and bruising on the lateral aspect of their ankle
- Radiographs of the ankle are indicated if the patient fulfils any of the Ottawa ankle rules
- Foot radiographs are obtained if the patient has tenderness at the base of the fifth metatarsal or at the navicular bone or if they are unable to bear weight on the foot
- Ankle sprains are often treated conservatively with rest, ice, compression and elevation
- Surgery is indicated in patients with persistent pain and recurrent ankle sprains

INJURIES ASSOCIATED WITH INDIVIDUAL SPORTS

Golf

The shoulder and the back are the common sites of overuse injuries. Golfer's elbow or medial epicondylitis is due to a common flexor origin tendinosis that also commonly occurs in weightlifters and rodeo athletes.

Tennis

Tennis elbow or lateral epicondylitis is angiofibrous dysplasia of the common extensor origin. Treatment consists of bracing, activity modification, injection (with some centres using platelet-rich plasma) and surgery if conservative measures fail.

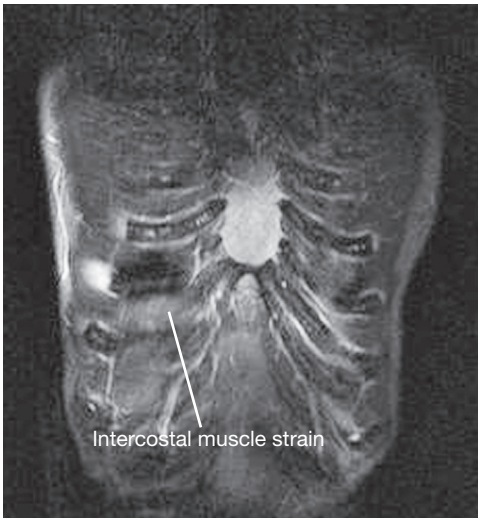

Figure 36.8 Coronal magnetic resonance imaging scan of the chest showing an intercostal muscle injury in a rower.

Partial ruptures of the calf muscles, especially the medial head of the gastrocnemius, are also found in tennis players (called tennis leg), and in patients who take part in other sports requiring sudden extreme acceleration.

Rowing

The common injuries that are encountered in rowing but that are rare in other athletics include rib stress fractures and intercostal muscle tears (*Figure 36.8*), which occur from the repetitive engagement of the latissimus dorsi muscles. Forearm tendon issues such as intersection syndrome (a tendinosis where the first and second extensor tendon compartments of the forearm cross) are also a commonly encountered problem in rowing athletes.

American football

This contact sport produces a variety of unique injuries, the main ones of which are closed head injuries, fractures, hip dislocations, twisting injuries to the knees and ankles leading to ligament tears, and turf toe.

Rugby

This is a high-intensity contact sport. Patients present with neck injuries including fractures of the cervical spine; acromioclavicular joint and finger injuries including dislocation of the phalanges; and tendon injuries such as jersey finger, in which there is injury to the flexor digitorum profundus tendon.

Javelin

Javelin throwers experience various injuries to the kinetic chain given the violent and abrupt throwing approach. Injuries due to abnormal stresses on the elbow are similar to those seen in baseball. This causes abnormalities of the hip, shoulder, UCL and phalanges.

Swimming

Shoulder injuries are more common in swimmers, especially in those performing the crawl or the butterfly stroke because of multidirectional instability, which can provide a competitive advantage for swimming but can become pathological.

Ballet dancing

Ballet dancers have problems with posterior impingement of the ankle and tendinopathy of the flexor hallucis longus tendon when working *en pointe* (tiptoe). Stress fractures are also found in female dancers as a result of repetitive training and can be more frequent in the female athlete triad (osteoporosis, disordered eating and amenorrhoea) (***Figure 36.9***).

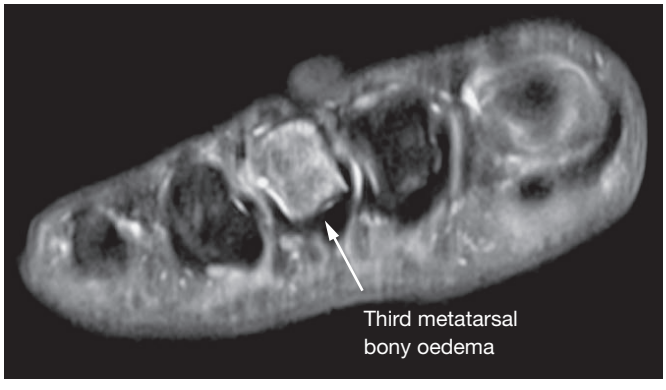

Figure 36.9 Magnetic resonance imaging short T1 inversion recovery axial sequence showing a stress injury to a metatarsal.

Snowboarding and skiing

Participants in both snowboarding and skiing have the full range of injuries associated with these high-speed sports. The rigid high boots used by skiers protect the ankle but increase the loads transmitted up the limb, risking fracture of the tibia and ligament disruption of the knee (especially the anterior cruciate). Novice snowboarders tend to get wrist fractures, while all levels of snowboarder can injure the acromioclavicular joint.

Marathon running

Most common problems include electrolyte abnormalities during events and iliotibial band syndrome and stress fractures in the feet and shins chronically.

SUMMARY

Athletic activities commonly result in a variety of injuries. For providers who take care of athletes, a basic knowledge of both common injuries and treatment algorithms as well as various sport-specific injury patterns is necessary to provide optimal care.

ACKNOWLEDGEMENT

The authors are grateful for and wish to acknowledge the contribution of Dylan Rakowski MD in the preparation of this chapter.

FURTHER READING

1 Goldenberg BT, Lacheta L, Rosenberg SI *et al.* Comprehensive review of the physical exam for glenohumeral instability. *Phys Sportsmed* 2020; **48**(2): 142–50.
2 Norte GE, West A, Gnacinski M *et al.* On-field management of the acute anterior glenohumeral dislocation. *Phys Sportsmed* 2011; **39**(3): 151–62.
3 Godin JA, Altintas B, Horan MP *et al.* Midterm results of the bony Bankart bridge technique for the treatment of bony Bankart lesions. *Am J Sports Med* 2019; **47**(1): 158–64.
4 Martetschläger F, Kraus TM, Hardy P, Millett PJ. Arthroscopic management of anterior shoulder instability with glenoid bone defects. *Knee Surg Sports Traumatol Arthrosc* 2013; **21**(12): 2867-76.
5 Bhatia S, Greenspoon JA, Horan MP *et al.* Two-year outcomes after arthroscopic rotator cuff repair in recreational athletes older than 70 years. *Am J Sports Med* 2015; **43**(7): 1737–42.
6 Jones KJ, Osbahr DC, Schrumpf MA *et al.* Ulnar collateral ligament reconstruction in throwing athletes: a review of current concepts. AAOS exhibit selection. *J Bone Joint Surg Am* 2012; **94**(8): e49.
7 Philippon MJ, Maxwell RB, Johnston TL *et al.* Clinical presentation of femoroacetabular impingement. *Knee Surg Sports Traumatol Arthrosc* 2007; **15**(8): 1041–7.
8 Millett PJ, Willis AA, Warren RF. Associated injuries in pediatric and adolescent anterior cruciate ligament tears: does a delay in treatment increase the risk of meniscal tear? *Arthroscopy* 2002; **18**(9): 955–9.
9 Chen ET, Borg-Stein J, McInnis KC. Ankle sprains: evaluation, rehabilitation, and prevention. *Curr Sports Med Rep* 2019; **18**(6): 217–23.